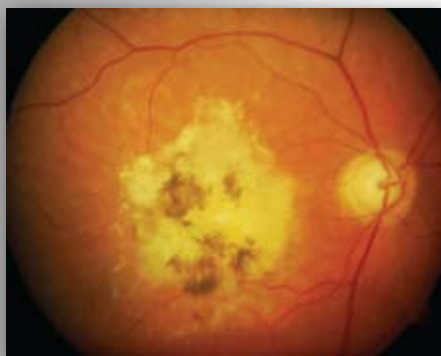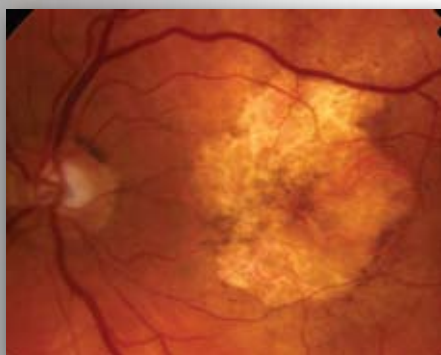


Advanced AMD

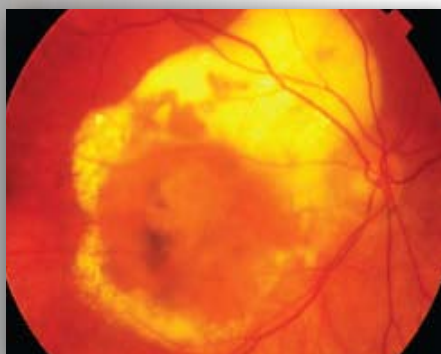
Refer if fulfils guidelines on form



Disciform Scar: Extensive subretinal fibrosis and pigment change at the macula. This shows advanced disease.



Geographic atrophy: Another form of advanced AMD (Dry) showing extensive retinal atrophy / thinning at the macula.



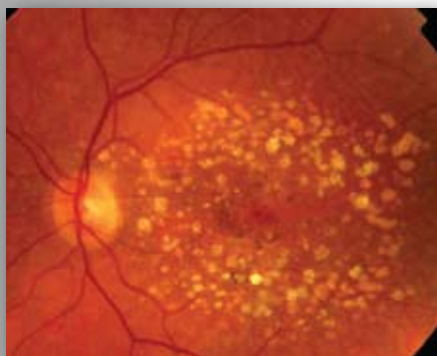
Advanced wet AMD - central macular elevation with/without subretinal fluid, hard exudate and some fibrosis.

If best corrected visual acuity is worse than 6/96, these patients may require a hospital assessment on a non-urgent basis.

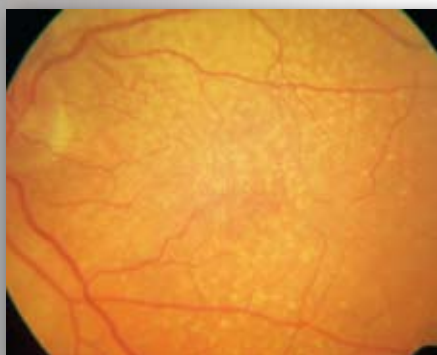
They may benefit from LVA assessment, visual impairment counselling and/or registration.

Drusen

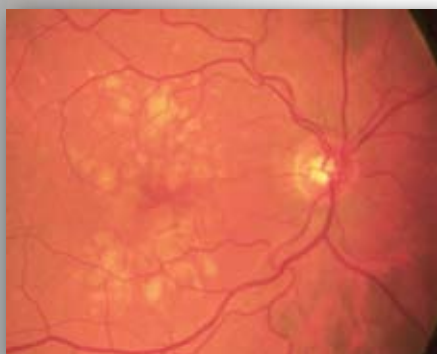Refer only if fulfils guidelines on form



Multiple drusen and pigment change.



Multiple fine hard drusen.



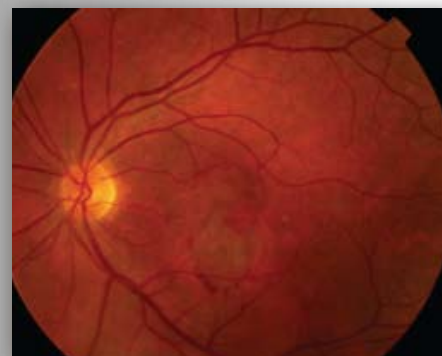
Large soft drusen.

These appearances are consistent with Age Related Maculopathy (ARM). Patients with drusen commonly notice distortion when shown an Amsler grid. This is less significant than spontaneously reported visual distortion.

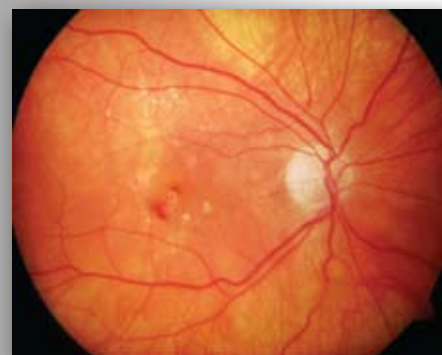Only refer if patient has noticed sudden onset of distortion or blurring of central vision. If the patient smokes they should be encouraged to give up as smoking has been shown to be a risk factor in the development of AMD. These patients may benefit from ocular nutritional supplements.

Wet AMD

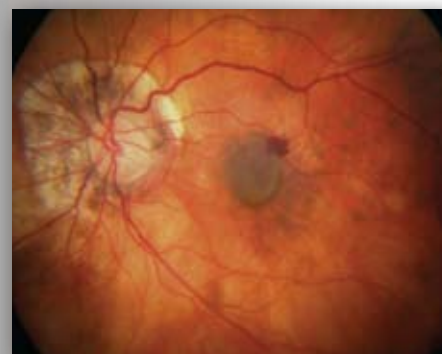Refer if fulfils guidelines on form



Subretinal haemorrhage and subretinal fluid suggest choroidal neovascularisation. This patient requires urgent referral and assessment.



Intraretinal haemorrhage centrally and exudates deposition superiorly. There may be associated subtle subretinal fluid or thickening. The presence of exudates is an important sign of leakage from choroidal neovascularisation. Refer urgently.



Small areas of intra / subretinal haemorrhage amongst the drusen suggest choroidal neovascularisation. This patient requires urgent referral and assessment.

Blood, retinal swelling and exudates deposition at the macula suggest wet AMD requiring urgent referral.

Please refer according to local protocols or use the attached form and fax to the appropriate consultant.

WET AMD RAPID ACCESS REFERRAL FORM

Name of Consultant: Miss K Mandal or Mr P Palimar

Fax Number: 01925 662395

PATIENT DETAILS

NAME :

DOB :

HOSPITAL NO:
(If known)

ADDRESS :

CONTACT TEL NOS :

GP NAME:

GP SURGERY:

OPTOMETRIST DETAILS (please print, do not use a stamp)

NAME :

PRACTICE :

GOC NO:

ADDRESS:

TEL :

FAX :

AFFECTED EYE :

RIGHT

LEFT

PAST HISTORY IN EITHER EYE

PREVIOUS AMD

RIGHT

LEFT

MYOPIA

RIGHT

LEFT

OTHER _____

RIGHT

LEFT

Referral Guidelines

PRESENTING SYMPTOMS IN AFFECTED EYE (one answer must be 'yes')

Duration of visual loss:

Please specify _____

- | | | | | |
|---|-----|--------------------------|----|--------------------------|
| 1. Visual loss | YES | <input type="checkbox"/> | NO | <input type="checkbox"/> |
| 2. Spontaneously reported distortion | YES | <input type="checkbox"/> | NO | <input type="checkbox"/> |
| 3. Onset of scotoma (or blurred spot) in central vision | YES | <input type="checkbox"/> | NO | <input type="checkbox"/> |

FINDINGS Best corrected VA (must be 6/96 or better in affected eye)

- | | | | | |
|--------------------------------|-------|---|------|---|
| 1. Distance VA | RIGHT | <input type="text"/> / <input type="text"/> | LEFT | <input type="text"/> / <input type="text"/> |
| 2. Near VA | RIGHT | <input type="text"/> | LEFT | <input type="text"/> |
| 3. Macular drusen (either eye) | RIGHT | <input type="checkbox"/> | LEFT | <input type="checkbox"/> |

In the affected eye ONLY, presence of:

- | | | | | |
|--|-----|--------------------------|----|--------------------------|
| 4. Macular haemorrhage (preretinal, retinal, subretinal) | YES | <input type="checkbox"/> | NO | <input type="checkbox"/> |
| 5. Subretinal fluid | YES | <input type="checkbox"/> | NO | <input type="checkbox"/> |
| 6. Exudate | YES | <input type="checkbox"/> | NO | <input type="checkbox"/> |

Comments

